

Radiographic Changes of the Nasal Septal Swell Body In Patients With Sinonasal polyposis

Yasser Mohammed Hassan Mandour

Ahmed Soliman El Kady

Hamada Mohamed Khater

Mohamed Afify Mohamed Afify

Samer Badie Kamel

See next page for additional authors

Follow this and additional works at: <https://pajr.researchcommons.org/journal>



Part of the [Oral and Maxillofacial Surgery Commons](#), [Otolaryngology Commons](#), and the [Otorhinolaryngologic Diseases Commons](#)

Radiographic Changes of the Nasal Septal Swell Body In Patients With Sinonasal polyposis

Authors

Yasser Mohammed Hassan Mandour, Ahmed Soliman El Kady, Hamada Mohamed Khater, Mohamed Afify
Mohamed Afify, Samer Badie Kamel, and Abdelrahman Ahmed Abdelal

ORIGINAL STUDY

Radiographic Changes of the Nasal Septal Swell Body in Patients with Sinonasal Polyposis

Yasser M.H. Mandour^{a,*}, Ahmed S. El Kady^a, Hamada M. Khater^b,
Mohamed A.M. Afify^a, Samer B. Kamel^a, Abdelrahman A. Abdelalim^a

^a Otorhinolaryngology, Faculty of Medicine, Benha University, Benha, Egypt

^b Radiology, Faculty of Medicine, Benha University, Egypt

Abstract

Background: The nasal septal body (NSB) is a dilated section of the anterior nasal septum that is situated anterior to the middle turbinate and around 0.7–1.5 cm above the nasal floor.

Aim: This study analyses the measures taken from patients without sinonasal polyposis in order to identify the structural alterations in the NSB among patients with sinonasal polyposis.

Patients and methods: This retrospective study was conducted between April 2021 and February 2022 involving a review of paranasal sinus computed tomography (PNS CT) scan among patients with sinonasal polyposis and without sinonasal disease. The anterior part (A) was measured anterior and superior to the inferior turbinate; the middle or widest (M) part was measured anterior to the middle turbinate and superior to the inferior turbinate; and the posterior (P) part was measured within the anterior 1/3 of the middle turbinate but not beyond the crista galli. The study has been conducted over two groups, group A: study group of 200 patient (146 male and 54 female) according to inclusion and exclusion criteria, group B: control group of 50 volunteers (17 male and 33 female) without any clinical and radiological findings related to PNS disease.

Results: The mean A part was statistically significant higher in group A than that in group B (5.34 ± 0.93 Vs. 3.44 ± 0.60 , $P < 0.001$), the mean M part was statistically significant higher in group A than that in group B (13 ± 1.9 Vs. 9.91 ± 0.90 , $P < 0.001$), the mean P part was statistically significant higher in group A than that in group B (5.54 ± 1.09 Vs. 3.95 ± 0.63 , $P < 0.001$), the mean P part of septum was statistically significant higher in group A than that in group B (3.26 ± 0.89 Vs. 2.22 ± 0.76 , $P < 0.001$)

Conclusion: There was statistically significant positive correlation between A part, M part, P part and P part of septum. There was statistically significant negative correlation between P part of septum and age while there was nonstatistically significant correlation between A part, M part, P part and age

Keywords: Radiology, Septal body, Sinonasal polyposis

1. Introduction

The septal swell body (SB), which is an expanded area of the anterior nasal septum, can be found via anterior rhinoscopy, nasal endoscopy, and sinonasal imaging tests.

The nasal septal body (NSB) is fusiform in shape, situated anterior to the inferior turbinate of the nose and superior to the middle turbinate, and it is 12.4 mm wide, 19.6 mm tall, and 28.4 mm long, with a distance of 24.8 mm 4 from the nasal floor.

It is composed of mucosa that is thicker and cartilage and bone that are typically only a few millimetres thick [1].

The septal body, which is normally a few millimetres thicker than the rest of the septum, is made up of septal cartilage. Additionally, the mucosa covering the septal body is thicker than the mucosa covering the remainder of the septum [2].

There is not much information on the NSB in the literature; the research mostly focused on histology and gross anatomical morphology. Due to its

Received 6 September 2022; accepted 28 October 2022.
Available online 10 November 2023

* Corresponding author at: Otorhinolaryngology, Faculty of Medicine, Benha University, Benha, Egypt.
E-mail address: ghader_massoud@yahoo.com (Y.M.H. Mandour).

<https://doi.org/10.58595/2090-7559.1220>

2090-7559/© 2023 Pan Arab Rhinology Society. This is an open access article under the CC-BY-NC-ND license (<http://creativecommons.org/licenses/by-nc-nd/4.0/>).

vasoactive and glandular characteristics, the septal body is a dynamic structure that controls nasal airflow and humidifies inspired air [3].

The morphometric and histological changes of the mucosal lining as well as the ultrastructure of the NSB are not well understood by rhinologists [4].

Similar mucosal modifications to those seen in inferior turbinates' hypertrophy can also occur in cases of persistent sinonasal illnesses in the septal body [e.g. allergic rhinitis (AR) and chronic rhinosinusitis (CRS)], Fibrosis, which results from ongoing inflammation, is the primary cause of turbinate mucosal growth. Traditional therapies such as nasal decongestants and corticosteroids may be less effective since the size increase brought on by fibrosis is harder to reverse [5].

Most radiographic studies on NSB did not include the linear dimensions of the front and posterior sections of the fusiform-shaped septal structure, as well as the less vasoactive portion of the septum. These findings might suggest that these components undergo significant changes as a result of chronic inflammation [6].

This study compared the measures taken from patients without sinonasal polyposis to evaluate the structural alterations occurring in the NSB among patients with the condition.

2. Patients and methods

This retrospective analysis examined individuals with sinonasal polyposis and those without sinonasal illness using paranasal sinus computed tomography (PNS CT) scans between April 2021 and February 2022. The investigation involved two groups:

Group A: study group of 200 patient (146 male and 54 female) according to inclusion and exclusion criteria.

Group B: control group of 50 volunteers (17 male and 33 female) without any clinical and radiological findings related to PNS disease.

From patients between the ages of 15 and 70 who visit the ear, nose, and throat (ENT) outpatient clinic at Benha University Hospitals and do not meet any of the exclusion criteria listed below. All patients have given their informed consent to take part in this trial. Additionally, the Otorhinolaryngology (O.R.L) department at Benha University's ethics committee gave its permission.

2.1. Inclusion criteria

- (1) Patients age will be between 15 and 70 years.
- (2) Patients with sinonasal polyposis grade 1 and 2.

Grade 1, restricted to the middle meatus, grade 2, extending below the middle turbinate, and grade 3, large polyps that completely covered the nasal cavity, according to the Malm scale.

2.2. Exclusion criteria

- (1) Patients with obvious polyposis who cannot distinguish their septum (grade 3 according to malm scale).
- (2) Patients who had nasal surgery.
- (3) Patients who had severe septal deviation.

After a thorough history was taken, both groups were evaluated by anterior rhinoscopy and nasal endoscopy and studied by CT PNS.

NSB was separated into the following three sections:

[Figs. 1–4](#)

2.3. Statistical analysis

An 'investigation report form' was used to capture the information. Using the computer application SPSS (Statistical package for social science) version 26, these data were tabulated, coded, and then analyzed to produce descriptive statistics for the data in the form of mean, standard deviation (SD), and number and percent. One of the following tests was used to determine the significance of difference in the statistical comparison between the several groups: The Student's *t*-test was used to compare the means of two groups of numerical data, while the χ^2 test was used to evaluate categorical data between groups (χ^2 -value). Different parameters were correlated using the Pearson correlation coefficient (*r*) test. Statistical significance was defined as *P* 0.05.

3. Results

The youngest patient of group A was 15 years old, and the oldest was 60 years old (mean, 38.3 years; SD, 14.7 years) 27% of the patient were female and 73% of the patient were male. The youngest patient of group B was 20 years old, and the oldest was 70 years old (mean, 39.4 years; SD, 15.8 years) 66% of the patients were female and 34% of the patients were male.

Statistically, there was no significant difference with respect to age and sex in this study.

Table 1: Reveals that there was nonstatistically significant difference regarding age while there was statistically significant difference regarding sex in between group A and B.

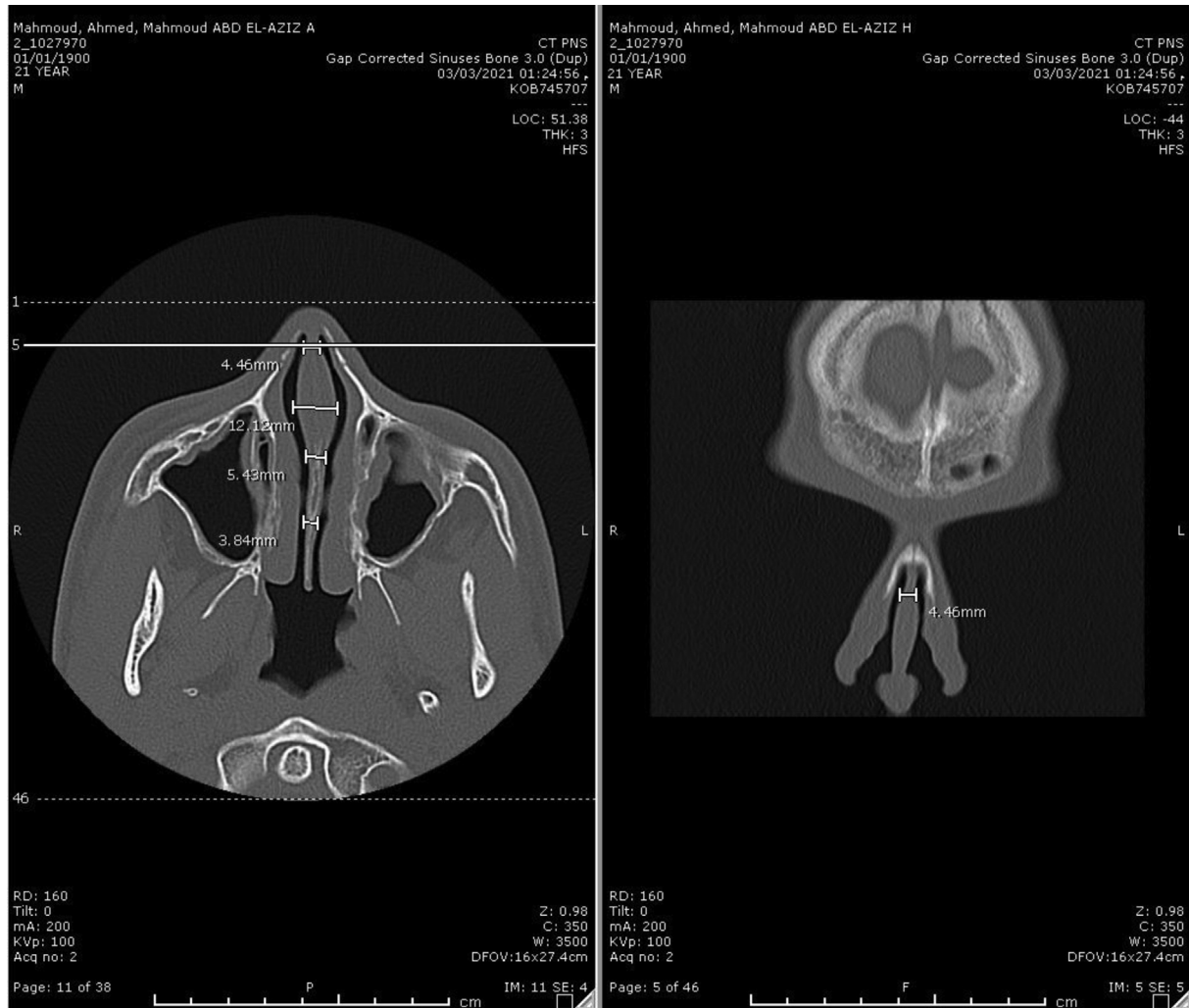

Fig. 1. Anterior part (A), located anterior and superior to inferior turbinate.

Table 2: Reveals that there was statistically significant difference in the mean Anterior part in between group A and B.

Table 3: Reveals that there was statistically significant difference in the mean Middle part in between group A and B.

Table 4: Reveals that there was statistically significant difference in the mean Posterior part in between group A and B.

Table 5: Reveals that there was statistically significant difference in the mean Posterior part of septum in between group A and B.

Table 6: Reveals that there was statistically significant positive correlation between Anterior part, Middle part, Posterior part, and Posterior part of septum. There was statistically significant negative correlation between Posterior part of septum and age while there was nonstatistically significant correlation between Anterior part, Middle part, Posterior part, and age.

4. Discussion

In the literature, this prominent component of the anterior nasal chamber has been referred to as the nasal septal swell body, anterior septal tubercle, septal turbinate, intumescencia nasi anterior, and Kisselbach's body [7].

However, no proof of its effect on nasal airflow has been established, despite the septal body's function appearing to be characterized by these traits. No *in vivo* research on the nasal aerodynamics of the septal swell body or assessment of the changes in a healthy, ill, or congested state has been done as of yet. These experiments are significant in establishing the notion that NSB can alter nasal airflow and resistance. The venous sinusoids and glandular properties of the NSB and inferior turbinate are similar in their histological and functional characteristics in the following ways: both can change in size and shape in response to the nasal cycle; both

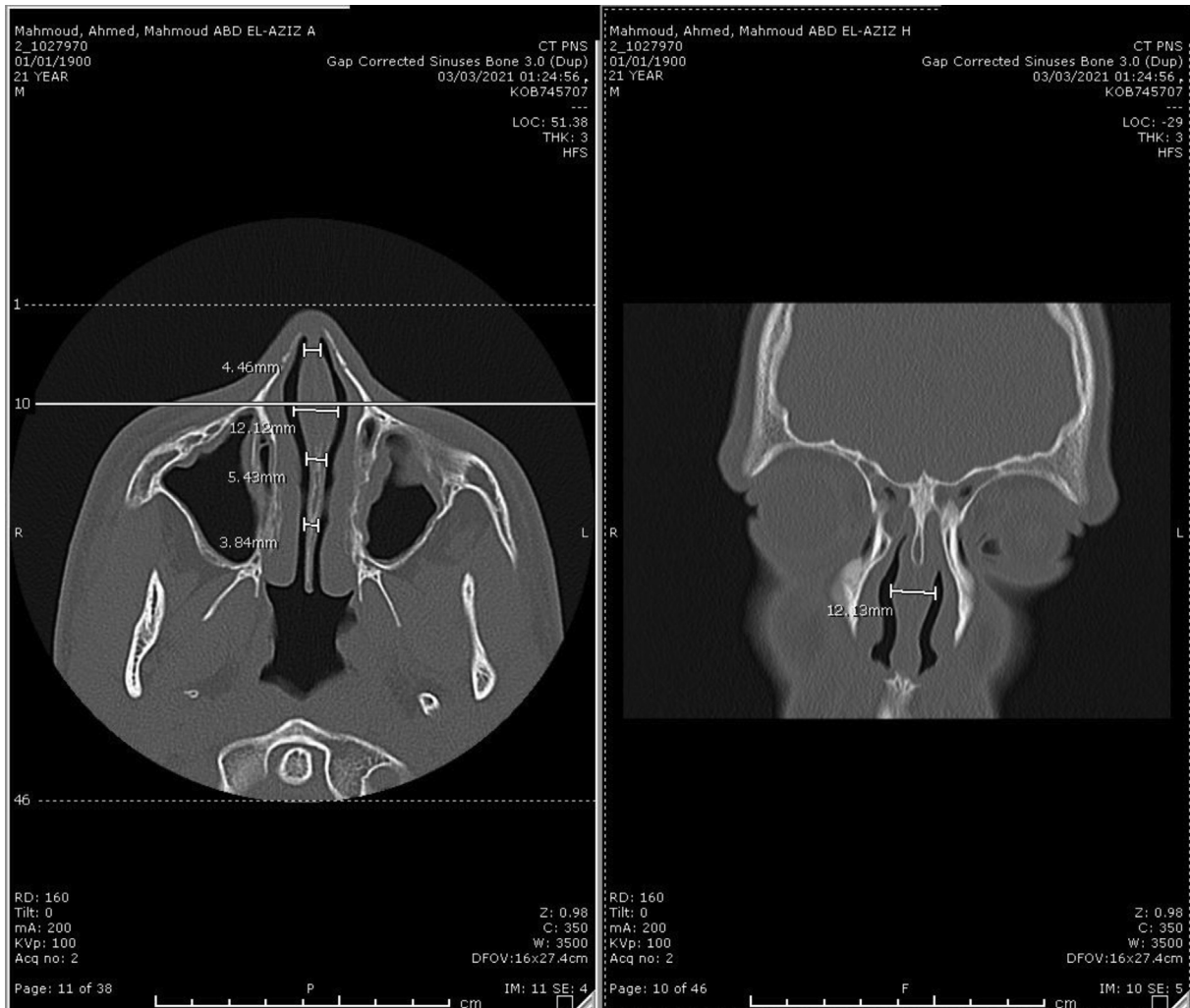


Fig. 2. Middle or widest part (M), located anterior to middle turbinate and superior to inferior turbinate.

have venous sinusoids and glandular properties, though NSB to a lesser extent; these findings led the researchers to postulate that NSB may play a role in nasal aerodynamics [8].

The inspiratory and expiratory air currents become turbulent in the internal nasal valve (INV), a crucial nasal anatomical trait. Any more narrowing of this area will significantly affect nasal airflow, causing a reported nasal obstruction, NSB should be considered a component of INV, together with the septum, upper lateral cartilage, and caudal inferior turbinate [9].

Chronic inflammatory sinonasal diseases like AR or CRS with or without polyposis can generate nasal mucosal edema, which can afterwards hyper-trophically change because of the ongoing inflammatory insult [10].

In the majority of earlier studies on the morphology of NSB, the maximum width was only radiographically measured. In this study, additional

measurements were made that appeared to be useful in describing the NSB's fusiform structure.

By using this method, we were able to prove that each segment/area measured in the NSB has undergone significant, independent modifications. Additionally, patients in the sick group were receiving long-term treatment at the time the computed tomography (CT) scan for the current investigation was done. Therefore, any thickness observed could be explained by mucosal remodeling brought on by the chronicity of the condition.

In this study the mean A part was statistically significant higher in group A than that in group B (5.34 ± 0.93 Vs. 3.44 ± 0.60 , $P < 0.001$). The mean M part was statistically significant higher in group A than that in group B (13 ± 1.9 Vs. 9.91 ± 0.90 , $P < 0.001$), the mean P part was statistically significant higher in group A than that in group B (5.54 ± 1.09 Vs. 3.95 ± 0.63 , $P < 0.001$), the mean P

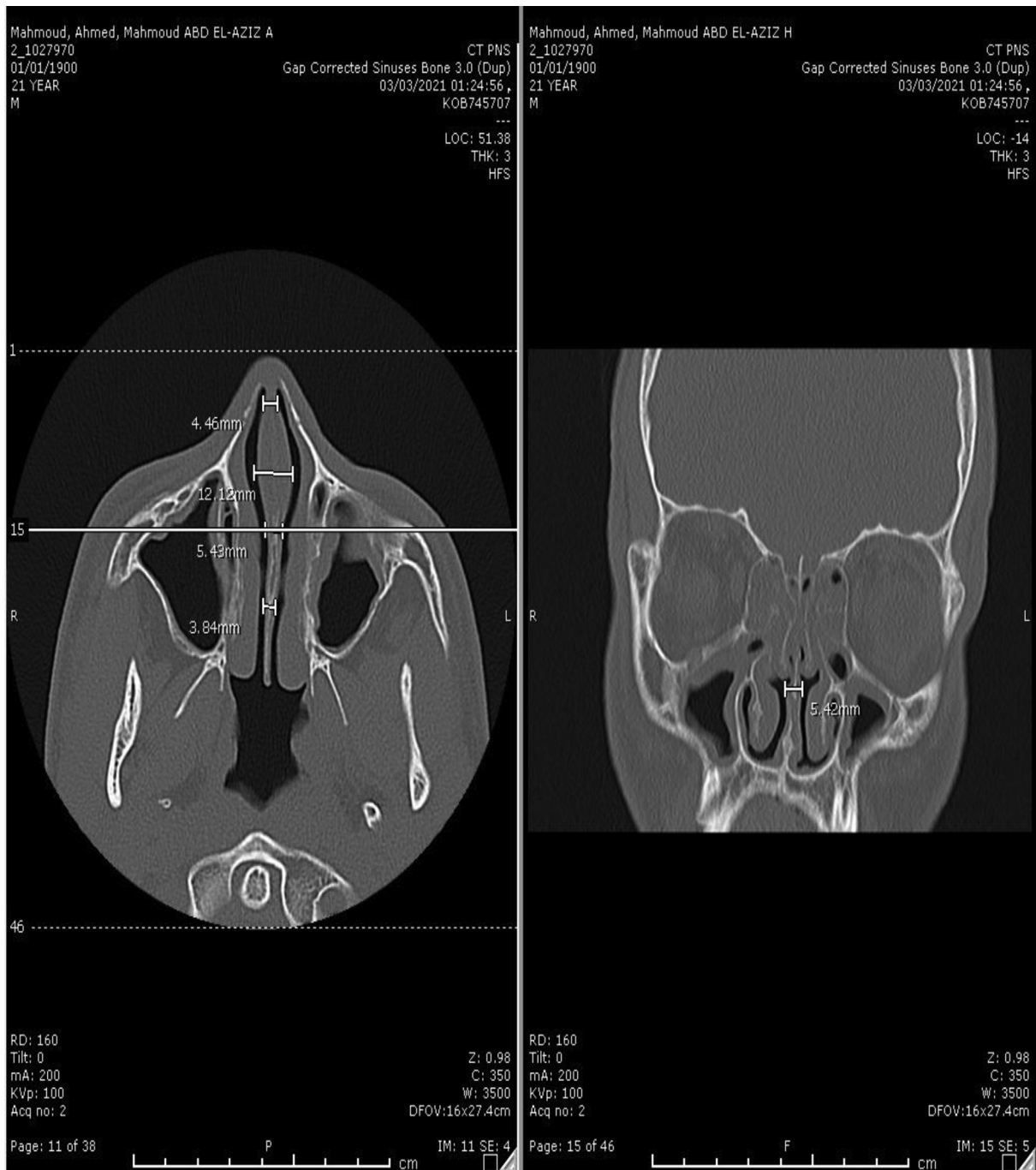


Fig. 3. Posterior part (P), located within the anterior 1/3 of middle turbinate not going beyond the crista galli.

part of septum was statistically significant higher in group A than that in group B (3.26 ± 0.89 Vs. 2.22 ± 0.76 , $P < 0.001$), there was statistically significant positive correlation between A part, M part, P part, and P part of septum. There was statistically significant negative correlation between P part of septum and age while there was nonstatistically significant correlation between A part, M part, P part and age.

In the control group, the diameter seems to decrease as the individual becomes older when NSB measurements are evaluated by age group. The findings back up the generally held belief that the mucosal epithelium atrophies with ageing [11].

The disease group, however, showed the opposite trend, confirming earlier studies that adult CRS with nasal polyposis exhibits mucosal remodeling that is more pronounced than pediatric or adolescent CRS

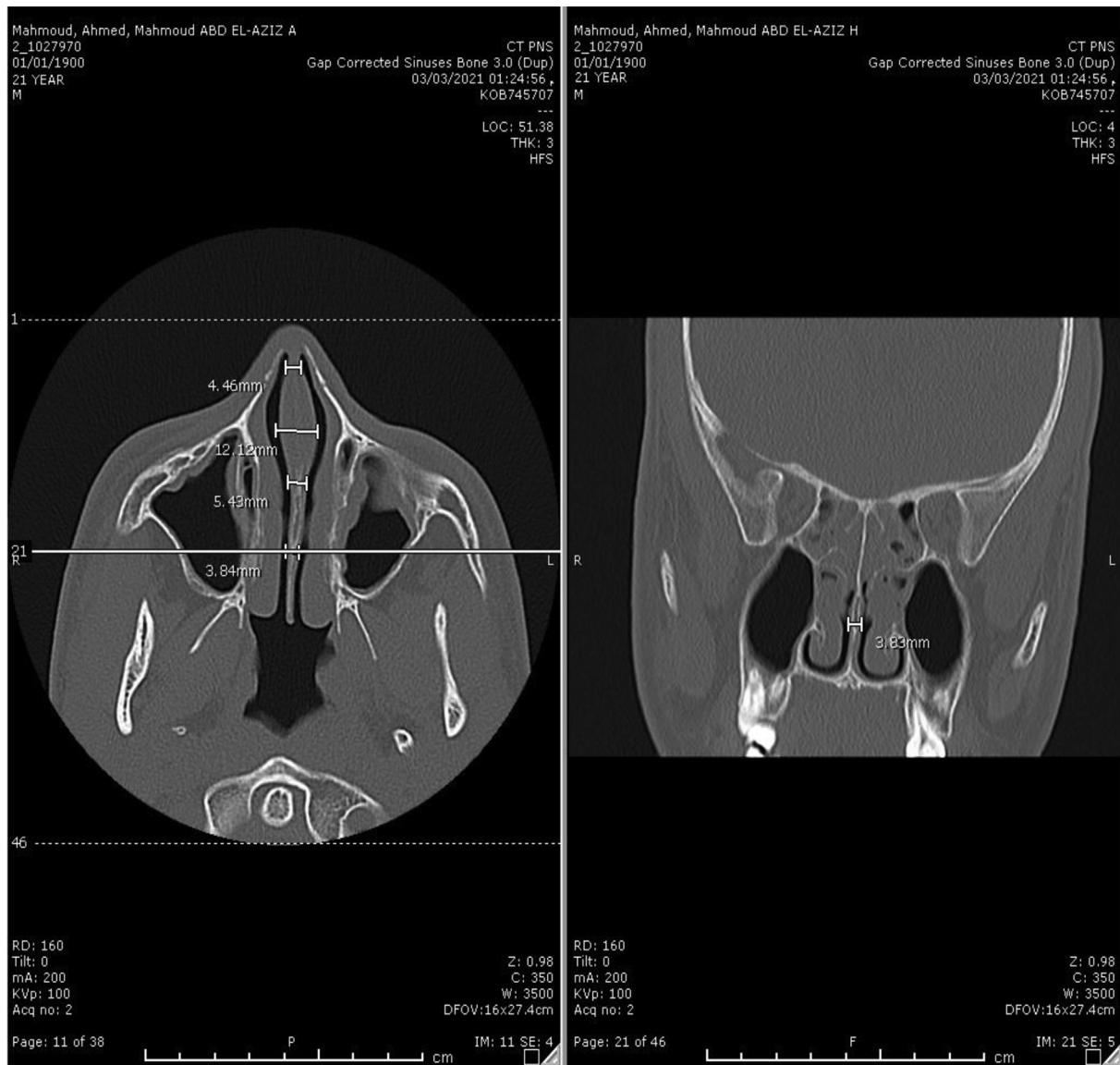


Fig. 4. Posterior part of the septum (sP) was measured at the area of horizontal attachment of middle turbinate to the lateral nasal wall and superior turbinate.

with nasal polyposis, including thickening of the basement membrane, increased extracellular matrix deposition, and goblet cell hyperplasia [12].

Due to a lack of consensus among ENT physicians and rhinologists, who generally view surgical treatment of NSB as aggressive and disputed, the condition is rarely surgically treated [13].

The lack of agreement may be caused in part by inconsistent histological study findings. According to earlier studies, the NSB's primary role is to humidify and regulate the temperature of inspired air because the structure contains more seromucinous glands than venous sinusoids [14].

They assist in maintaining the health of these glands and preventing mucosal dryness and crust

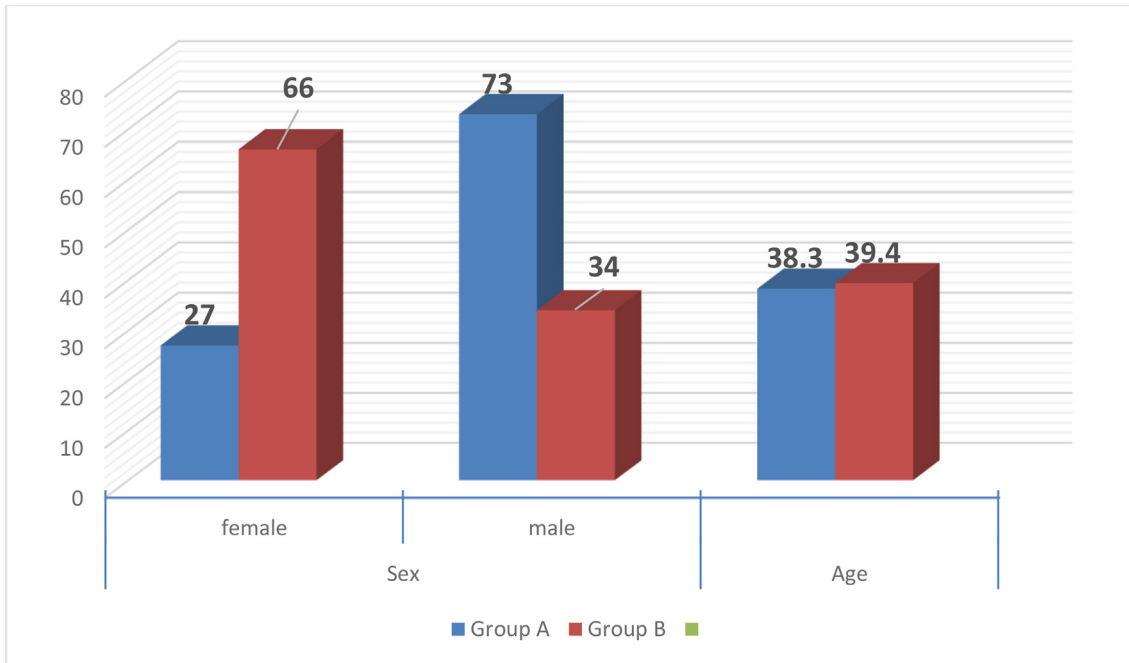
formation. A substantial number of venous sinusoids were discovered in the swell body, according to earlier research, suggesting that it has the capacity to alter nasal airflow [15].

Due to the potential to affect nasal aerodynamics, some writers opt to treat NSB surgically. Only three publications have examined the effects of NSB reduction to date. In one trial, cryotherapy for the NSB and inferior turbinate had no impact in treating nasal irritation and obstruction [16].

This study is underpowered, nevertheless, as it requires numerous surgical methods. Another study used a microdebrider to combine septal body volume reduction with turbinoplasty in patients with inferior turbinate and septal body hypertrophy,

Table 1. Comparison of age and sex in study groups

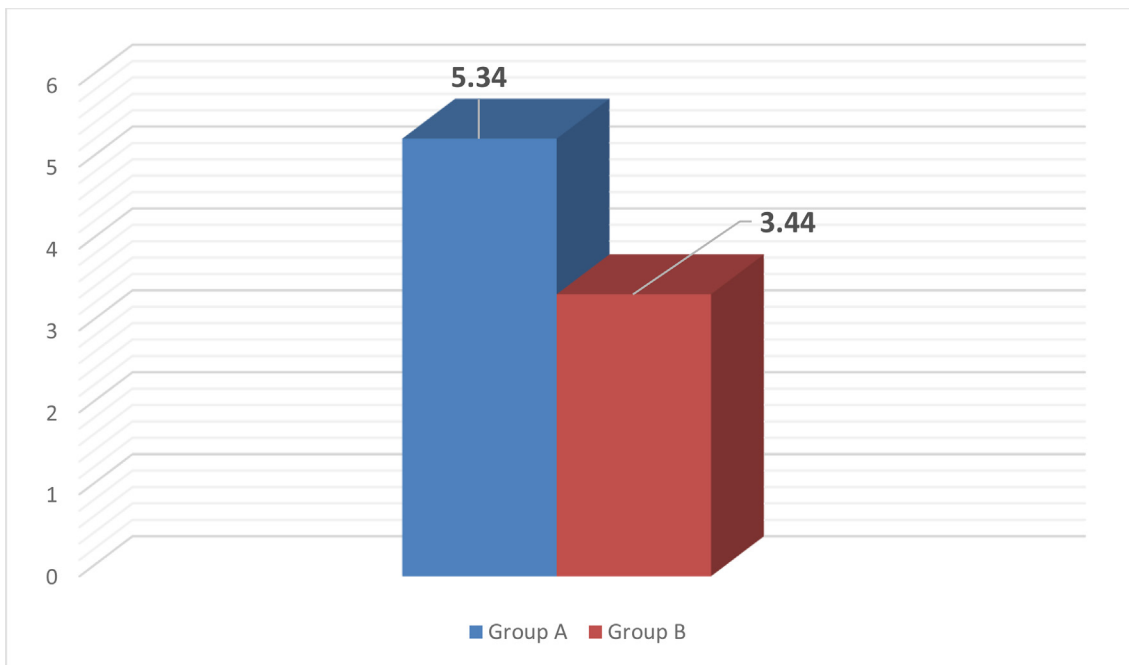
	Group A (n = 200) No. (%)	Group B (n = 50) No. (%)	Test of significance	P value
Sex				
Female	54 (27.0%)	33 (66.0%)	26.8	<0.001*
Male	146 (73.0%)	17 (34.0%)		
Age (mean ± SD)	38.3 ± 14.7	39.4 ± 15.8	0.5	0.3



* Means significance.

Table 2. Comparison of Anterior part in study groups

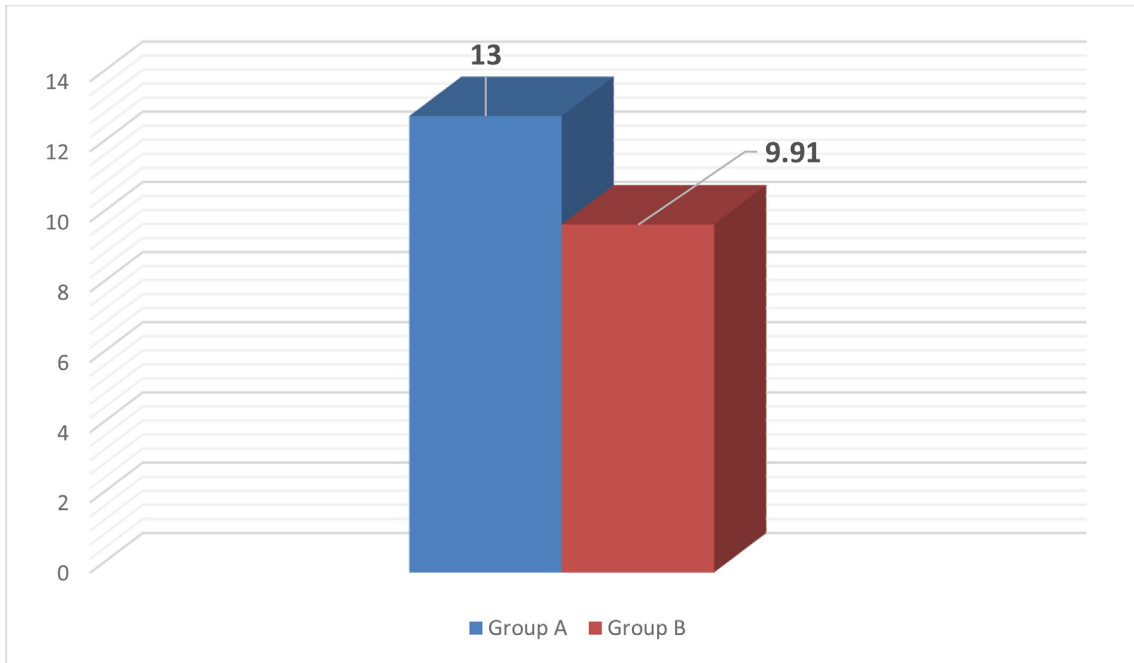
	Group A (n = 200)		Group B (n = 50)		T test	P value
	Mean	SD	Mean	SD		
Anterior part	5.34	0.93	3.44	0.60	17.6	<0.001*



* Means significance.

Table 3. Comparison of Middle part in study groups

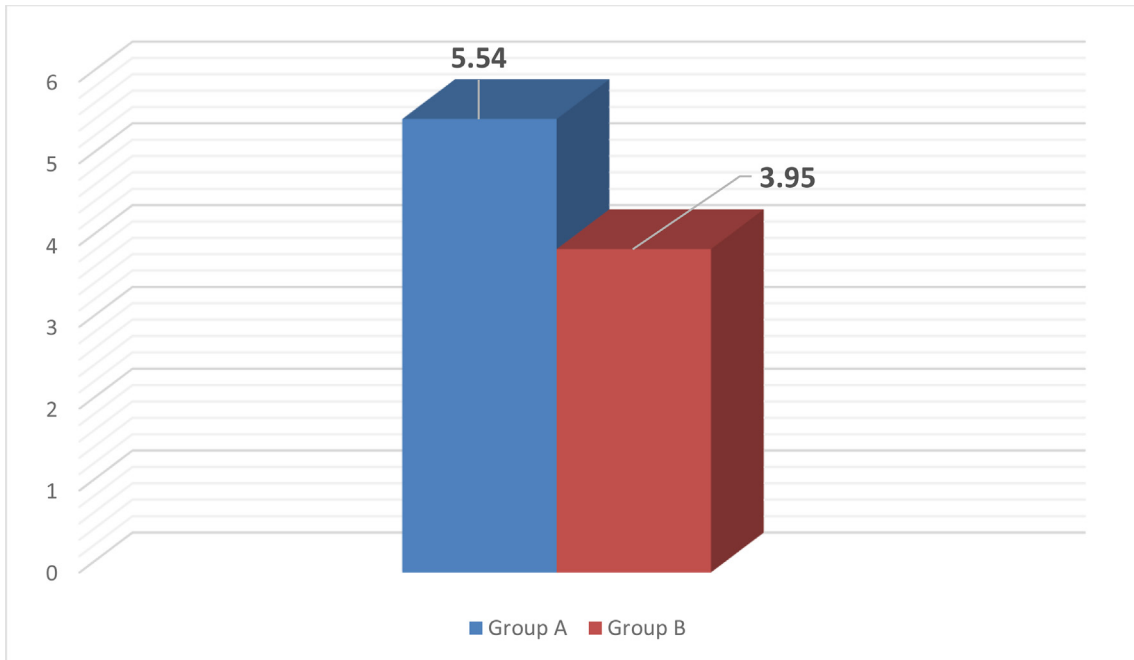
	Group A (n = 200)		Group B (n = 50)		T test	P value
	Mean	SD	Mean	SD		
Middle part	13.00	1.90	9.91	0.90	16.7	<0.001*



* Means significance.

Table 4. Comparison of Posterior part in study groups

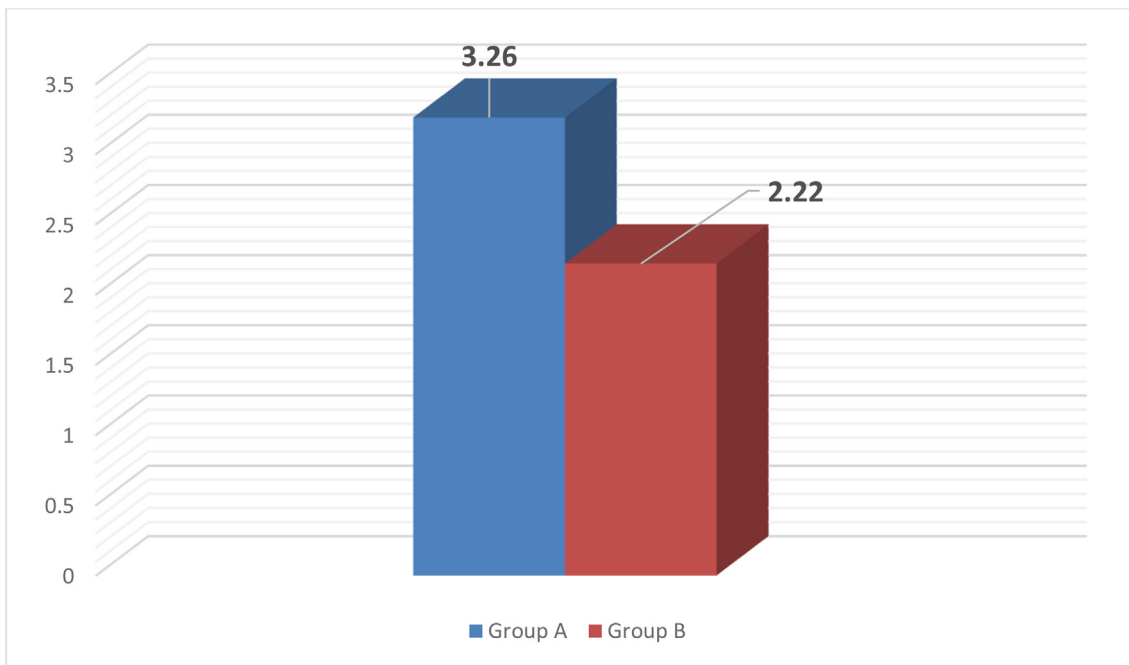
	Group A (n = 200)		Group B (n = 50)		T test	P value
	Mean	SD	Mean	SD		
Posterior part	5.54	1.09	3.95	0.63	13.6	<0.001*



* Means significance.

Table 5. Comparison of Posterior part of septum in study groups

	Group A (n = 200)		Group B (n = 50)		T test	P value
	Mean	SD	Mean	SD		
Posterior part of septum	3.26	0.89	2.22	0.76	8.3	<0.001*



* Means significance.

Table 6. Correlation between different parameters

	Anterior part		Middle part		Posterior part		Posterior part of septum	
	r	P value	r	P value	r	P value	r	P value
Age	-0.08	0.20	0.004	0.95	0.03	0.65	-0.14	0.030*
Anterior part	-	-	0.61	<0.001*	0.59	<0.001*	0.41	<0.001*
Middle part	0.61	<0.001*	-	-	0.66	<0.001*	0.49	<0.001*
Posterior part	0.59	<0.001*	0.66	<0.001*	-	-	0.69	<0.001*
Posterior part of septum	0.41	<0.001*	0.49	<0.001*	0.69	<0.001*	-	-

* Means significance.

which seemed to be more effective than turbino-plasty alone [17].

In a trial, radiofrequency ablation of the septal swell body was used to treat refractory nasal obstruction. They created an office-based surgical technique that is both efficient and secure for reducing NSB [18].

The results of this investigation make it challenging to make certain judgments about the clinical implications of NSB overdevelopment. The primary objective of the study is to demonstrate that nasal polyps and persistent sinonasal disease are associated with NSB overdevelopment in individuals. The results of the most recent study, according to the scientists, offer further details that may help with a

better comprehension of this largely neglected structure.

4.1. Conclusion

There was statistically significant positive correlation between A part, M part, P part, and P part of septum. There was statistically significant negative correlation between P part of septum and age while there was nonstatistically significant correlation between A part, M part, P part, and age

Ethical considerations

Ethics approval and consent to participate: Local ethical committee approval and Informed

consent had been obtained before the onset of this study.

Consent for publication

Not applicable.

Availability of data and material

Data are available on request.

Funding

No external source of funding

Conflicts of interest

No conflict of interest and nothing to disclose.

References

- [1] Wexler D, Braverman I, Amar M. Histology of the nasal septal swell body (septal turbinate). *Otolaryngol Head Neck Surg* 2006;134:596–600.
- [2] Berger G, Hammel I, Berger R, Avraham S, Ophir D. Histopathology of the inferior turbinate with compensatory hypertrophy in patients with deviated nasal septum. *Laryngoscope* 2000;110:2100–5.
- [3] Elwany S, Salam SA, Soliman A, Medanni A, Talaat E. The septal body revisited. *J Laryngol Otol* 2009;123:303–8.
- [4] Setlur J, Goyal P. Relationship between septal body size and septal deviation. *Am J Rhinol Allergy* 2011;25:6.
- [5] Farmer SE, Eccles R. Chronic inferior turbinate enlargement and the implications for surgical intervention. *Rhinol* 2006;44:234–8.
- [6] Arslan M, Muderris T, Muderris S. Radiological study of the intumescencia septi nasi anterior. *J Laryngol Otol* 2004;118:199–201.
- [7] Setlur J, Goyal P. Relationship between septal body size and septal deviation. *Am J Rhinol Allergy* 2011;25:397–400.
- [8] Cole P. The four components of the nasal valve. *Am J Rhinol* 2003;17:107–10.
- [9] Miman MC, Deliktas H, Ozturan O, Toplu Y, Akarçay M. Internal nasal valve: revisited with objective facts. *Otolaryngol Head Neck Surg* 2006;134:41–7.
- [10] Kim DK, Rhee CS, Han DH, Won TB, Kim DY, Kim JW. Treatment of allergic rhinitis is associated with improved attention performance in children: the Allergic Rhinitis Cohort Study for Kids (ARCO-Kids). *PLoS One* 2014;9:e109145.
- [11] Pinto JM, Jeswani S. Rhinitis in the geriatric population. *Allergy Asthma Clin Immunol* 2010;6:10.
- [12] Rehl RM, Balla AA, Cabay RJ, Hearp ML, Pytynia KB, Joe SA. Mucosal remodeling in chronic rhinosinusitis. *Am J Rhinol* 2007;21:651–7.
- [13] Wotman M, Kacker A. Should otolaryngologists pay more attention to nasal swell bodies? *Laryngoscope* 2015;125:1759–60.
- [14] Pawankar R, Nonaka M. Inflammatory mechanisms and remodeling in chronic rhinosinusitis and nasal polyps. *Curr Allergy Asthma Rep* 2007;7:202–8.
- [15] Costa DJ, Sanford T, Janney C, Cooper M, Sindwani R. Radiographic and anatomic characterization of the nasal septal swell body. *Arch Otolaryngol Head Neck Surg* 2010;136:1107–10.
- [16] Haight JS, Gardiner GW. Nasal cryosurgery and cautery: should the septum be treated and is a diagnosis relevant? *J Otolaryngol* 1989;18:144–50.
- [17] Yu MS, Kim JY, Kim BH, Kang SH, Lim DJ. Feasibility of septal body volume reduction for patients with nasal obstruction. *Laryngoscope* 2015;125:1523–8.
- [18] Catalano P, Ashmead MG, Carlson D. Radiofrequency ablation of septal swell body. *Ann Otolaryngol Rhinol* 2015;2:1069.